

Current management and therapeutical perspectives in thrombotic thrombocytopenic purpura

Paul Coppo¹ⁱ, Agnès Veyradier^{2,3i}

1. UPMC université Paris-6, AP-HP, hôpital Saint-Antoine, département d'hématologie, 75012 Paris, France
2. Hôpital Antoine-Béclère, service d'hématologie biologique, 92140 Clamart, France
3. Université Paris-11, AP-HP, Inserm U770, 94276 Le Kremlin-Bicêtre cedex, France

Correspondence:

Paul Coppo, Hôpital Saint-Antoine, service d'hématologie et de thérapie cellulaire, 184, rue du Faubourg-Saint-Antoine, 75012 Paris, France.
paul.coppo@sat.aphp.fr

Available online: 21 January 2012

In this issue

Thrombotic microangiopathies: From empiricism to targeted therapies

P. Coppo, Paris, France

Genetics of hemolytic uremic syndromes

M. Malina et al., Prague, Czech Republic

Management of hemolytic uremic syndrome

C. Loirat et al., Paris, France

Paradigm shift of childhood thrombotic thrombocytopenic purpura with severe ADAMTS13 deficiency

H. Yagi et al., Nara, Japan

Advantages and limits of Adamts13 testing in the prognostic assessment of thrombotic thrombocytopenic purpura

P.M. Mannucci, Milan, Italy and M. Franchini, Parma, Italy

Current management and therapeutical perspectives in thrombotic thrombocytopenic purpura

P. Coppo, Paris, France and A. Veyradier, Clamart, France

Thrombotic microangiopathic syndromes associated with drugs, HIV infection, hematopoietic stem cell transplantation, and cancer
J.N. George et al., Oklahoma City, USA

Summary

Thrombotic thrombocytopenic purpura (TTP) is a particular form of thrombotic microangiopathy typically characterized by microangiopathic hemolytic anemia, profound peripheral thrombocytopenia, and a severe deficiency of the von Willebrand factor-cleaving protease ADAMTS13 (acronym for A Disintegrin And Metalloproteinase with Thrombospondin-1 motifs [13th member of the family]). ADAMTS13 deficiency is usually severe (< 10% of normal activity) and results from autoantibodies directed to ADAMTS13 (acquired TTP) or from biallelic mutations of the encoding gene. In some cases, acquired TTP occurs in association with specific conditions that must be identified for appropriate management: a HIV infection, a connective tissue disease, a pregnancy, a cancer or a treatment with antiplatelet agents. TTP requires a rapid diagnosis and an adapted management in emergency, which allows current remission rates of 80 to 90%. Maximal measures of resuscitation may be required. Daily sessions of therapeutical plasma exchange (TPE) until durable platelet count recovery remain the basis of management of acquired TTP. In the last few years, the anti-CD20 monoclonal antibody rituximab has been increasingly used in patients with a suboptimal response to standard treatment, such as those with refractory disease (~10% of cases) or an exacerbation of the disease despite intensive TPE (~50% of cases). Rituximab prevents 1-year but not long-term relapses. Further studies should specify the optimal schedule of rituximab administration and its role as a prophylactic treatment in asymptomatic patients with severe acquired ADAMTS13 deficiency that persists even in disease remission. In hereditary TTP, also known as Upshaw-Schulman syndrome (USS), a diagnosis early in life is mandatory. Prophylactic infusions of plasma should be performed in chronic relapsing forms to prevent long-term organ complications, which have to be assessed accurately and regularly. In the upcoming years, new targeted therapies evaluated through international trials should further improve the management of these diseases. Consensual guidelines for the treatment of very specific and rare situations (such as management during pregnancy in USS patients and prevention of relapses in chronic relapsing acquired TTP) should arise from the shared experience of national groups.

ⁱ Reference Center for Thrombotic Microangiopathies.

Thrombotic thrombocytopenic purpura (TTP) is a form of thrombotic microangiopathy (TMA) typically characterized by microangiopathic hemolytic anemia, profound peripheral thrombocytopenia, and a severe deficiency in the von Willebrand factor (VWF)-cleaving protease ADAMTS13 (A Disintegrin And Metalloproteinase with Thrombospondin-1 Motifs [ADAMTS13; 13rd member of the family]). In most cases, ADAMTS13 deficiency results from autoantibodies directed against ADAMTS13 [1–3]. Acquired TTP is usually idiopathic and likely occurs most often in patients with genetic risk factors for autoimmunity [4], although it can also occur in association with HIV infection, connective tissue diseases, pregnancy, cancer, or after treatment with an antiplatelet agent. In hereditary TTP, also termed Upshaw-Schulman syndrome (USS), ADAMTS13 deficiency results from recessive biallelic mutations of the *ADAMTS13* gene (box 1) [5].

Pathophysiologically, TTP typically results from endothelial stimulation in a patient with a predisposing factor (e.g., a severe ADAMTS13 deficiency) though the factors (typically, microbial antigens) initiating this process may not systematically identified. A “two-hit” scenario was strongly suggested by a mouse model of TTP in which the disease occurred in animals with severe ADAMTS13 deficiency only after endothelial stimulation [6]. However, findings in a baboon model of anti-ADAMTS13 antibody-mediated TTP challenged this view, with baboons developing TTP rapidly after the administration of anti-ADAMTS13 antibodies without any apparent endothelial stimulation [3].

In the “two-hit” model, it is hypothesized that stimulated endothelial cells acquire a pro-aggregant phenotype through the release of highly adhesive VWF multimers and other pro-aggregant compounds. In patients with severe ADAMTS13 deficiency, these features lead to persistent platelet aggregation with thrombi formation and occlusion of systemic microvessels. The link between VWF and TTP pathophysiology was provided by the seminal works of Moake [7,8], who found that patients with chronic relapsing TTP had elevated levels of circulating high molecular weight VWF during both the acute phase of the disease and remission. Since these unusually large

Box 1

Categories of thrombotic thrombocytopenic purpura

Congenital ADAMTS13 deficiency

- Early-onset congenital TTP
- Late-onset congenital TTP¹

Acquired ADAMTS13 deficiency

- Idiopathic TTP
- Ticlopidine-associated TTP
- HIV-associated TTP²
- Connective tissue disease-associated TTP³
- Cancer-associated TTP

ADAMTS13: A Disintegrin And Metalloproteinase with Thrombospondin-1 motifs 13; HIV: human immunodeficiency virus; TTP: thrombotic thrombocytopenic purpura.

¹Rare cases of late-onset congenital TTP have been reported; pregnancy (particularly during the second half) is a typical triggering factor.

²HIV infection is a predisposing factor for acquired TTP, particularly in patients with only moderate immune deficiency. Since these patients may not have developed opportunistic diseases yet, a diagnosis of TTP requires the ruling out of a HIV-associated infection.

³Systemic lupus erythematosus is the most typical connective tissue disease associated with acquired TTP. Systemic lupus erythematosus may occur before or after an episode of TTP, but both diseases occurring concomitantly is unusual.

VWF multimers are absent in normal plasma, Moake hypothesized that an undiscovered (at that time) plasma protease was involved in the cleavage of hyper-adhesive VWF multimers. This protein, subsequently termed ADAMTS13, was partially purified in 1998 by both Tsai and Furlan independently [1,2], and its gene was cloned in 2001 [5]. It was found to be a specific zinc metalloproteinase that specifically cleaves unfolded, high molecular weight VWF multimers between the tyrosine 842 and methionine 843 residues of the A2 domain in high shear stress conditions, as observed in microcirculation (figure 1). As a consequence, dysfunction of ADAMTS13 leads to persistent VWF-dependent platelet accumulation that eventually causes microvascular thrombosis and TTP.

Clinical presentation

The incidence of TTP has been reported to be four cases per million people per year. Acquired TTP occurs more frequently in females (3:2 female-to-male ratio) and usually occurs in the fourth decade. While the onset of disease is typically sudden, prodromic manifestations, including fatigue, arthralgias, myalgias, and abdominal and/or lumbar pain, that suggest a flu-like

Glossary

HIV	human immunodeficiency virus
IVIg	intravenous immunoglobulins
USS	Upshaw-Schulman syndrome
TMA	thrombotic microangiopathy
TPE	therapeutic plasma exchange
TTP	thrombotic thrombocytopenic purpura
VWF	von Willebrand factor

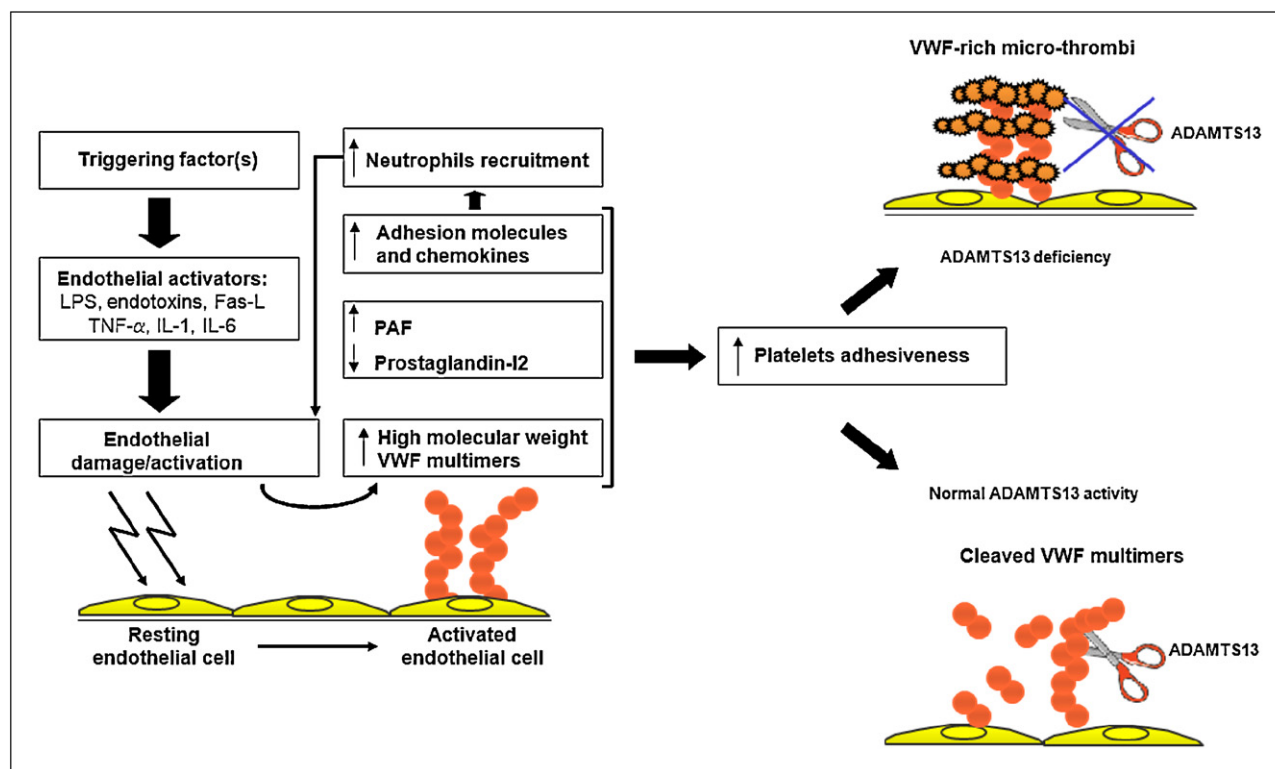


FIGURE 1

Proposed model of the pathophysiological mechanisms leading to microthrombi formation in Thrombotic thrombocytopenic purpura (TTP)

Endothelial cells may be activated by triggering factors, mainly infections. Bacterial lipopolysaccharide, various cytokines, and Fas-ligand may act in concert to activate endothelial cells. Damaged endothelial cells release high molecular weight VWF multimers along with platelet activating factor and other compounds involved in endothelial damage/activation and express adhesion molecules on their cell surface. In patients with severe ADAMTS13 deficiency, high molecular weight VWF accumulates, resulting in platelet hyper-adhesiveness and platelet clumping in the microvasculature of various organs, including the brain, kidneys, digestive tract, and heart.

LPS: lipopolysaccharide; TNF: tumor necrosis factor; IL: interleukin; PAF: platelet activating factor; VWF: von Willebrand factor.

episode are frequently observed at the time of diagnosis or during the preceding days.

Microangiopathic hemolytic anemia and peripheral thrombocytopenia are associated with variable organ injury according to the series and to the classification adopted by the authors [9]. Cerebral manifestations have been reported in 50–80% of cases and range from headache to coma through confusion, seizure, focal deficiency and altered mental state. Renal manifestations are the most variable and depend on inclusion criteria. In patients with severe acquired ADAMTS13 deficiency, renal involvement is usually mild [10–13]. Cardiac involvement has been widely reported in autopsy studies, but has been evaluated in very few systematic studies. Cardiac events may include infarction, congestive heart failure, arrhythmias, cardiogenic shock, and sudden cardiac arrest [14–16]. It has been reported that an elevated serum troponin level upon

presentation was an accurate predictor of subsequent acute myocardial infarction [16]. Digestive tract involvement, including abdominal pain, nausea, vomiting, and diarrhea was reported in up to 24% of cases. Autopsy studies revealed that thrombi can involve almost all organs: the brain (mainly cerebral cortex), heart, kidneys, and the digestive tract, they can also be found in the spleen, pancreas, and adrenal glands (*box 1*) [9]. Histopathologically, thrombi are composed primarily of platelets and VWF, which is in contrast with the thrombi of disseminated intravascular coagulopathy or hemolytic-uremic syndrome, which are characterized by prominent fibrin deposits [17].

The above clinical features are not specific for TTP, and TTP presentation may overlap with that of other TMA syndromes, including hemolytic-uremic syndrome. However, there is accumulating evidence that severe acquired ADAMTS13 deficiency is associated with specific clinical features, such as mild renal

involvement and profound thrombocytopenia. Patients with such disease also differ from patients with detectable ADAMTS13 activity in that they suffer from more disease exacerbations during treatment and more relapses [10–13]. Further studies are required to better characterize patients with an idiopathic TMA and detectable ADAMTS13 activity. Indeed, there is an increasing body of evidence that suggests that this subset of patients actually are likely to be afflicted with various distinct diseases that have specific pathophysiological mechanisms. For example, the involvement of complement protein dysfunction cannot be excluded in some patients, which may account for the evolution to end stage renal failure that occurs in some patients [10]. Similarly, the incidence of malignant hypertension or microangiopathic antiphospholipid-associated syndrome, a more recently identified form of TMA [18], remains to be determined in such patients. Lastly, some patients may have a low but detectable level of ADAMTS13 activity, and it cannot be excluded that subtle dysfunctions of ADAMTS13 caused by yet unknown mechanisms may have a role in TMA process.

Diagnostic criteria

Historically, TTP was defined as the pentad of microangiopathic hemolytic anemia, peripheral thrombocytopenia, fever, neurological involvement, and renal failure. However, as the awareness of clinicians in regard to TTP diagnosis improved, it became clear that this classical pentad was present at diagnosis in only 40% of patients [9]. With the availability of effective treatment, the rapid diagnosis of TTP by sensitive criteria became mandatory, and this urgency required a decrease in the stringency of the diagnostic criteria. Consequently, the association of microangiopathic hemolytic anemia with peripheral thrombocytopenia should be enough to strongly suggest a diagnosis of TTP. In line with this view, patients with an apparent diagnosis of idiopathic thrombocytopenic purpura or Evan's syndrome who are not responding to the usual therapies should be investigated for schistocytes on repeated blood smears. In those patients, identification of schistocytes on blood smear in association with severe ADAMTS13 deficiency should lead to revisiting the diagnosis [19].

Treatment of acquired autoimmune thrombotic thrombocytopenic purpura in adults

Very few randomized studies with definitive conclusions have been performed in the field of TTP due to the rarity of the disease. Indeed, its management is largely based on empiricism and clinical experience.

Plasma therapy

Therapeutic plasma exchange (TPE) remains the cornerstone of the current management of TTP. The introduction of this

procedure in the early 1980s led to an impressive improvement in the prognosis of the disease with remission rates of more than 85%, which is in stark contrast to the pre-TPE era's death rate of 90% within 3 months of diagnosis [9]. The value of plasma therapy that involves large volumes of plasma was demonstrated in a randomized, prospective comparison of plasma infusion and TPE for the treatment of adult patients with TTP. This study found that TPE had a higher response rate than plasma infusion by day 9 of treatment (47% versus 27%, respectively, $P = 0.025$) and a higher survival rate at 6 months after entry in the study (78% versus 49%, respectively, $P = 0.002$) [20]. Though this study does not shed any light on whether TPE improves the disease by removing toxic substances, pro-aggregant substances, and/or antibodies directed against ADAMTS13 from the plasma, it clearly demonstrates a plasma volume-dependent response of TTP. Further, it has been reported that replacement with albumin instead of plasma was ineffective, supporting the idea that the efficacy of TPE is mainly due to its ability to supply large volumes of plasma and replenish the missing enzyme in patients.

TPE must be started as soon as the diagnosis of TTP is established or even suspected. Delay in the initiation of plasma therapy may contribute to a poor outcome. If TPE cannot be immediately performed, high dose plasma infusions should be started emergently until TPE availability. However, this procedure can be rapidly associated with fluid overload. Thus, a switch to TPE should be done as rapidly as possible [21]. For example, we begin infusing plasma into patients who require transfer from a primary center to a reference center for the management of TTP while they are being transported in the ambulance. Moreover, plasma infusions may be useful in patients for whom the diagnosis of TTP is uncertain and may be helpful as a diagnosis test in patients who start to improve after plasma infusion. The immediate outcome may not be predictable, and severe forms may require intensive care measures [22]. Therefore, it may be advantageous to manage such patients in intensive care units during the first few days after diagnosis and until the platelet count reaches 50 giga/l. The TPE procedure usually requires $1.5 \times$ plasma volume exchange for the first procedures and then a plasma volume replacement of $1.0 \times$ combined with 4% albumin thereafter. TPE is performed daily until organ involvement has resolved and the platelet count has stably recovered. Whether the frequency of TPE sessions should be rapid or progressively decreased remains a matter of debate. Some groups stop the TPE sessions as soon as remission is obtained and resume plasma therapy if patients worsen thereafter. Others progressively decrease the frequency of TPE, usually over a few weeks, based on the rationale that this schedule may prevent the severe and sometimes fatal rebounds in patients who experience a flare-up of the disease when the TPE sessions are stopped. In both cases, many cycles of stopping/decreasing

and resuming daily TPE sessions are sometimes required before the reaching of a stable remission.

A theoretical benefit for the use of cryosupernatant plasma has been suggested because it is depleted of VWF, and a retrospective survey suggested it had greater efficacy than TPE [23]. However, a finding from a small, randomized trial that compared the two treatments suggested equivalent outcomes [24].

Additional therapies

Besides TPE, standard first-line therapy may include other therapeutics such as steroids and antiplatelet agents. However, no study has provided definitive evidence of their efficacy. Therefore, their association with TPE in the treatment of TTP is mainly based on empiricism and clinical use.

Steroids

There is a rational basis for the use of steroids in treatment of acquired TTP. Steroids are immunosuppressive, and it has been clearly established that in most cases severe ADAMTS13 deficiency is related to autoantibodies directed against the enzyme. It has also been suggested that the effectiveness of steroids may be in part due to the down-regulation of various cytokines involved in TTP pathogenesis. However, these relevant hypotheses are not supported by the results of clinical trials, rendering the level of proof of the efficacy of steroids in the treatment of TTP quite low. In fact, studies in which steroids were not given in conjunction with TPE reported outcomes comparable to those of studies in which steroids were introduced [20]. Moreover, relapses have been observed during treatment with steroids [25].

Steroid administration remains variable between groups. In a report by Bell et al., 54 patients with a diagnosis of TTP but without cerebral involvement were initially treated with high dose corticosteroids (200 mg oral prednisone or intravenous prednisolone per day for 5–7 days) with a progressive decrease of the daily dose over the ensuing weeks. Thirty patients (55%) responded to steroids in 48–72 hours, whereas the remaining 24 patients did not improve and required TPE [25]. This study, which was performed before the current era of systematic TPE in TTP, indicates that the administration of high dose steroids alone has some efficacy in the treatment of TTP, at least in patients without significant organ involvement. Balduini et al. conducted a prospective randomized study of 60 patients that compared the effectiveness of standard-dose (1 mg/kg/day) to high-dose methylprednisolone (10 mg/kg/day for 3 days and then 2.5 mg/kg/day thereafter) as an adjunctive treatment to TPE in newly diagnosed TTP patients. After 23 days of treatment, failure to achieve complete remission was observed in 23% of patients in the high-dose methylprednisolone group and 53% of patients in the standard-dose group [26]. Though this study did not answer the question of whether a lower dose of steroids increase the likelihood of remission compared to no steroid treatment, it does at least suggest that high-dose

steroid therapy improves the management of TTP. The effectiveness of high-dose corticosteroids in TTP is also supported by other published studies that suggested that patients refractory to TPE could respond rapidly to boluses of corticosteroids [27,28]. Taken together, those results argue for a role of steroids in the management of TTP in association with TPE provided there is no obvious contra-indication, though the modalities of administration still remain controversial.

Antiplatelet agents

The use of antiplatelet agents in TTP (and TMA in general) is based on the rationale that the main pathological feature of the disease is the presence of platelet thrombosis in the micro-circulation. Aspirin and dipyridamole are the two main compounds considered potentially effective in the treatment of TTP. While aspirin is known to act through the irreversible acetylation of cyclo-oxygenase that results in impaired prostaglandin production by platelets and the endothelium, dipyridamole is reported to increase the intraplatelet concentrations of cyclic adenosine monophosphate. However, in TTP, the pivotal mechanism for platelet clumping involves the glycoprotein Ib/IX-VWF axis, which challenges the relevance of aspirin and dipyridamole in the treatment of TTP. In fact, this discrepancy may account for the variability in the results of the studies that evaluated the efficacy of these antiplatelet agents in the treatment of TTP. A study of 72 TTP patients randomized to receive TPE and steroids with or without aspirin and dipyridamole reported a trend of lower mortality at 15 days in the patients treated with antiplatelet agents compared to those who were not (one death versus five deaths, respectively) that was not accompanied by an increase in bleeding [29]. However, as statistical significance could not be reached in this study, definitive conclusions could not be achieved. Meanwhile, other authors have reported that aspirin and dipyridamole were ineffective and increased the risk of bleeding in TTP [25,30].

Other measures

The anemia in TTP may be profound, and red blood cell transfusions should be performed to maintain a hemoglobin level of approximately 8 g/dL. On the other hand, platelet transfusions were reported to sometimes be associated with fatal episodes. From those reports, it is sometimes difficult to relate the clinical history and to assess accurately whether platelet transfusions directly impacted the outcome of the disease. Moreover, it is likely that platelet transfusions were only performed in patients suffering from severe disease. However, the suddenness of the worsening of patients after platelet transfusion, which can occur within minutes to hours, strongly suggests that the transfused platelets precipitated the organ failure and death [31–34]. Indeed, a report by Bell et al. described 11 patients who presented with a precipitous decline in clinical status after platelet transfusion. In nine of the

patients, there was an abrupt worsening of clinical status and renal function, suggesting that the transfused platelets induced organ injury [25]. Taken together, these studies suggest that platelets may enhance and promote the microangiopathic process. This could be at least in part explained by the fact that platelets are activated by the harvesting of them from donors and during storage, leading to the release of pro-aggregant substances. Based on this data, our approach is to avoid platelet transfusions in patients with TTP unless they present with a major life-threatening bleeding. If platelets must be transfused for a surgical procedure, it is preferable that the transfusion is performed in association with TPE [35,36].

Also, patients should receive folate supplementation to prevent a deficiency related to hyperhemolysis.

Response to standard treatment

The response to TPE may differ between patients with high variability in the number of TPE procedures needed. The platelet count and LDH level are the most sensitive indicators of disease severity on which to base treatment decisions. Failure of the platelet count to increase and the LDH level to decrease (which occurs in 10 to 20% of cases) requires the intensification of treatment. Also, in 30–50% of cases, patients with acquired TTP may experience exacerbations of the disease despite daily TPE for unknown reasons. One may hypothesize that such exacerbations may be related to the removal of the anti-ADAMTS13 antibodies from plasma by plasmapheresis, which induces a rebound in the antibody titer. However, exacerbations of TTP were also reported with patients treated with plasma alone, suggesting alternative mechanisms that could be related to an anamnestic response to the exogenous ADAMTS13 supply [37].

Refractoriness and exacerbations

Patients who experience refractory disease or an exacerbation after standard treatment are considered to have a suboptimal response to treatment. In our practice, we consider TTP as refractory when there is no response to treatment after four full days of standard treatment to treat the potentially slow responders early because they may experience a poor outcome and treatment-related complications. Exacerbations are usually defined as a worsening of the disease while the patient is under treatment, during a decrease in the TPE schedule, or before a patient has had a normal platelet count for 30 days. A worsening of the disease that occurs more than 30 days after platelet count recovery is usually defined as a relapse. Though arbitrary and based initially on only clinical experience, these definitions are being progressively and advantageously shared by most groups, which should allow a common language for fruitful meta-analyses in the future.

Patients with a suboptimal response to standard treatment require more intensive plasma therapy and/or immunomodulatory

therapies. Immunomodulatory therapies mainly include the chimeric monoclonal antibody directed against CD20 antigen on B lymphocytes, rituximab, and vincristine. More rarely, additional salvage therapies such as cyclophosphamide and splenectomy are also needed. The reported studies on these agents in the treatment of TTP involve series of patients that are usually heterogeneous and/or small. Consequently, no consensual guidelines can be formally drawn for the treatment of patients unresponsive to standard treatment. However, the increasing number of patients who have been reported to have been successfully treated with rituximab for severe TTP accounts for the fact that this drug is becoming the standard second-line treatment for patients with a suboptimal response to standard treatment [38].

Rituximab

A meta-analysis reported that among refractory patients, rituximab treatment led to complete remission in approximately 88% of patients. This remission was accompanied by a partial or total recovery of ADAMTS13 activity at 3 or 6 months, the disappearance of ADAMTS13 inhibitors, and a significant decrease in circulating anti-ADAMTS13 antibodies. Among relapsed patients, complete remission was achieved in all reported cases. Importantly, only rare serious side effects were reported during or after administration [38].

The outstanding results that rituximab demonstrated in the treatment of severe forms of TTP led to the rationale that rituximab may be of benefit earlier in the management of TTP. In our experience, we use rituximab as an adjuvant therapy for approximately 6 years in patients with a suboptimal response to standard treatment (as previously defined) along with daily TPE. Empirically, we perform four rituximab infusions at the dose of 375 mg/m² within 15 days. Rituximab allows for faster platelet count recovery and may have a plasma-sparing effect. This parallels with a faster and greater increase of ADAMTS13 activity and a more profound and rapid decrease in anti-ADAMTS13 antibodies [39,40]. Patients treated with rituximab usually achieve complete remission within 35 days of the start of TPE, which is in contrast with historical series in which slow responders may achieve complete remission beyond this time in up to 25% of cases. On average, platelet count recovery is observed 2 weeks after the first rituximab infusion. Rituximab prevents 1-year relapses, but long-term relapses still occur along with B-cell reconstitution [39,40]. Tolerance was good with only acceptable and classical side effects that mainly occurred during the first rituximab administration. No significant infectious complications occurred. These data provide evidence that rituximab should become a standard when the response to standard treatment is not optimal. However, several points will have to be addressed in future clinical trials. First, is rituximab only effective in patients with a severe acquired ADAMTS13 deficiency or could it also have a role in

the treatment of patients with detectable/normal ADAMTS13 activity? Second, is the empirical $375 \text{ mg/m}^2 \times 4$ dose, which is based on the use of rituximab in hematology-oncology, optimal, or should we use a schedule adapted to the level of residual circulating B-cell lymphocytes? Third, should patients in remission but with persisting severe acquired ADAMTS13 deficiency receive prophylactic infusions of rituximab, given the higher relapse rate in this population? Fourth, a patient with a delayed response to rituximab may require additional salvage therapies in the more severe cases until rituximab is efficient.

Vincristine

Vincristine has been used to treat different types of thrombocytopenia, including immunological thrombocytopenic purpura and secondary thrombocytopenias. Vincristine may act as a microtubule destabilizing agent as well as a modifier of platelet membrane glycoprotein receptors thus preventing platelet activation. Vincristine may also function as an immunomodulator.

In a retrospective study, eight patients who received vincristine (2 mg IV once weekly) after failing to respond to TPE had a survival rate of 50% [41]. Similarly, Welborn et al. reported eight patients who were refractory to plasmapheresis, antiplatelet agents and/or steroids who received vincristine weekly with a rapid and complete response in all cases [42]. In a literature review that involved 56 studies and 105 patients, Ziman et al. showed that patients receiving vincristine as secondary or salvage therapy (i.e., > 3 days following diagnosis) achieved stable remission in 73% of cases, with adverse events in only 5.7% of cases [43]. Though retrospective and uncontrolled, these studies provide some evidence for the use of vincristine as an effective salvage therapy in patients with acquired TTP who are not optimally responding to standard treatment.

Based on the apparent efficacy of vincristine as a secondary therapy, several authors have used it as part of a combination therapy with TPE as the initial treatment for TTP. When evaluated in its entirety, a literature review suggests an advantage for the combination of TPE and vincristine as the initial therapy compared to TPE alone in regard to the durable remission rate [43]. However, once again, the retrospective design and lack of a control group in most of these studies preclude any definitive conclusions on whether vincristine should be used as first-line therapy.

Splenectomy

The concept that the pathophysiology of TTP is immune in nature led to the empirical use of splenectomy in patients with severe refractory disease. However, there have been very few cases of refractory TTP treated with splenectomy during the acute phase that had a successful outcome, whereas there were several cases in which this treatment led to a fatal

outcome immediately after the procedure, which obviously challenges any assertions about the efficacy and relevance of splenectomy in the treatment of refractory TTP [25,44,45]. The mechanism by which splenectomy induces a rapid (and frequently transient) rise in the platelet count is unclear, and it is unknown if splenectomy can control the microangiopathic process of TTP.

Cyclophosphamide

There are very few retrospective studies that report on the efficacy of cyclophosphamide in the treatment of TTP. The effectiveness of cyclophosphamide against TTP may be explained by its lymphoablative properties. Further investigations are required to more precisely define the role of this drug in the management of severe cases of TTP. Meanwhile, cyclophosphamide is usually administered at high doses to patients with refractory, life-threatening TTP [46].

Intravenous immunoglobulins

There are some case reports that have suggested the efficacy of intravenous immunoglobulins (IVIg) in the treatment of TTP. However, a retrospective study of 17 patients could not provide clear evidence of IVIg having any beneficial effects in the management of TTP [47]. Thus, as of now, there is not enough positive data available for IVIg to be considered a possible adjunctive treatment for TTP.

Other immunomodulatory agents

There have been some anecdotal reports on the use of cyclosporin A, azathioprine, and mycophenolate mofetil in the treatment of patients with refractory TTP [48–51]. However, no systematic studies on the role of these compounds in this context have been conducted. Thus, no clear conclusions can be drawn about their possible efficacy. However, there are studies that support a role for cyclosporin A as first-line treatment in conjunction with TPE for the prevention of relapses and exacerbations and indicate that this treatment leads to an improvement in ADAMTS13 activity [52,53].

Intensification of therapeutical plasma exchange sessions

The relationship between the infusion of high volumes of plasma and better responses is the rationale for twice-daily TPE in patients with a suboptimal response to standard treatment. However, this cumbersome procedure may not be available in all centers. Moreover, this procedure has been evaluated in few studies. The most accurate account of twice-daily TPE sessions in refractory patients was reported by the Oklahoma group. In this study, 31 episodes of TTP in 28 patients were treated with twice-daily TPE. A definite response was observed in three episodes, whereas 27 episodes had a possible response, and one episode had no response. However, in the latter, an alternative etiology was eventually found (Rocky Mountain fever). Overall, among the 30 other patients, four died. As the authors stated, any possible benefit of the

procedure could not be clearly documented in most patients because other treatments were concomitantly initiated or intensified [54]. However, the survival rate in this subset of patients (one that usually has a poor prognosis) was high in this study (~87%), suggesting that twice-daily TPE could be considered a possible salvage therapy in this context.

Relapses

Up to 20–40% of patients with TTP experience a relapse. Undetectable ADAMTS13 activity that persists after remission is achieved is associated with more relapses during the first year, whereas patients whose ADAMTS13 activity recovers rarely relapse (40% versus 5%, respectively) [55,56]. Some patients also demonstrate a complete recovery of ADAMTS13 activity and years later experience a severe ADAMTS13 deficiency that is associated with a relapse. The period between relapses may range from days to many years. When a relapse occurs, TPE has to be resumed. In this context, further relapses may be prevented by various immunomodulating strategies, including rituximab, which is being increasingly prescribed in this context. Ongoing studies should determine whether patients with a persistent decrease in ADAMTS13 activity should be systematically treated with rituximab and the long-term consequences of such treatment in terms of infectious complications, particularly in patients who require repeated rituximab infusions to maintain a detectable level of ADAMTS13 activity. When a relapse occurs, there are no clear predictors of severity, and each relapse should be considered as potentially severe, irrespective of the presentation of the previous TTP episode [25]. However, some authors have suggested that relapses have a less severe course than the initial presentation, possibly because those patients are being closely watched [57].

Splenectomy

Splenectomy was reported to reduce the incidence of relapse in TTP patients with chronic relapses [58]. A study of six consecutive patients who had one or more relapses of TTP over a 10-year period demonstrated that splenectomy performed during remission reduced the frequency of relapses and the resulting need for medical therapy. In general, when performed in remission, splenectomy is a safe procedure [44,45,59] and should be considered in patients who have suffered repeated relapses.

Other immunomodulatory drugs

Single cases and small series have suggested that immunomodulatory drugs such as cyclosporine A, azathioprine, and mycophenolate mofetil could have benefit in the prevention of chronic relapses in acquired TTP [60–62]. However, the use of these drugs in this context requires further accurate evaluation through large studies.

Differential diagnosis of acquired thrombotic thrombocytopenic purpura versus late-onset Upshaw-Schulman syndrome and therapeutic consequences

USS can have an adult onset, especially in women, as pregnancy is a common trigger for the first well-identified bout of TTP [63]. In these adult patients, the volume of plasma given for the treatment of a TTP bout is usually less important than it is in the acquired autoimmune form, and plasma infusions alone (in other words, not TPE) are usually enough to achieve remission [64,65]. The observation of the latter along with the absence of detectable anti-ADAMTS13 autoantibodies in an adult patient experiencing a first TTP episode should lead one to suspect the very rare late-onset form of hereditary TTP. In this context, a familial inquiry should be performed (specifically focused on the presence of unexplained neonatal icterus and/or exchange transfusion in the propositus and any episodes of stillborn, early death, or icterus/anemia/thrombocytopenia in siblings) along with a genetic analysis. In contrast to patients with childhood-onset USS (see *infra*), these adult patients usually do not exhibit a chronic form of the disease and do not require monthly preventive plasma therapy. Thus, plasma therapy is only performed to treat acute events of TTP at the time of their occurrence. However, in USS women undergoing a pregnancy, preventive plasma therapy should be systematic beginning at the start of the second trimester to prevent both an acute TTP event in the mother and fetal loss (see *infra*) [63].

Specific treatments for thrombotic thrombocytopenic purpura with associated conditions and in different age ranges

HIV-associated thrombotic thrombocytopenic purpura

The early identification of TTP is particularly required in this subset of patients. Indeed, patients with a diagnosis of TMA should systematically be investigated for HIV infection since TMA, more specifically TTP, could be the initial sign of an HIV infection. Indeed, patients with HIV-associated TMA and severe ADAMTS13 deficiency are usually characterized by having little or no AIDS-related complications. On the other hand, patients with detectable ADAMTS13 activity have progressive opportunistic infections and HIV-related dysmyelopoiesis, indicating an advanced HIV infection with severe immune deficiency (as illustrated by a low CD4⁺ T lymphocyte count) [66,67]. Moreover, HIV⁺ patients harboring a severe ADAMTS13 deficiency usually respond to plasma therapy and have remission and survival rates comparable to those of patients with idiopathic TMA. Indeed, HIV status often does not alter the usually favorable prognosis of TMA with severe ADAMTS13 deficiency. Such patients should benefit from the usual measures in TTP management (e.g., intensive and possibly prolonged plasma therapy

with TPE, along with antiretroviral treatment) [66,68,69]. In contrast, patients with TMA in the setting of a more advanced HIV infection with AIDS-related complications usually display a poor response to plasma therapy [66,67], which places the use of prolonged TPE sessions in such patients under question.

Cancer-associated thrombotic thrombocytopenic purpura

Patients with TTP associated with cancer frequently have a typical presentation of weakness, dyspnea, bone pain, disseminated intravascular coagulopathy, and erythromyeloidemia. The cancer is frequently disseminated with marrow metastases. Prognosis is very poor, and mainly depends on cancer chemosensitivity [70,71].

Antiplatelet agent-associated thrombotic thrombocytopenic purpura

The antiplatelet agents ticlopidine and to a lesser extent clopidogrel can induce an autoimmune reaction to ADAMTS13. Anti-ADAMTS13 antibodies from patients with ticlopidine-associated TTP have been shown to be able to suppress the activity of ADAMTS13. This suppressive activity does not require the presence of ticlopidine and subsides after the discontinuation of ticlopidine. Prognosis is good with a remission rate of over 80% after standard treatment. Clopidogrel is more frequently associated with renal failure, detectable ADAMTS13 activity, and a poor response to TPE [72].

Pregnancy-associated thrombotic thrombocytopenic purpura

Pregnancy is a risk factor for TTP. Indeed, some cases of hereditary TTP are revealed during pregnancy. Moreover, patients with a known severe ADAMTS13 deficiency frequently relapse during the second half of pregnancy. Whether patients with a past history of acquired TTP are at significant risk of relapse during pregnancy requires further investigation.

The diagnosis of TTP may be challenging during pregnancy, and TTP should be distinguished from the HELLP (hemolysis, elevated liver enzymes, and low platelet count) syndrome, which requires specific management distinct from that used to treat TTP.

In patients with hereditary TTP, relapses during pregnancy should be prevented by plasma infusions every 2–3 weeks. Whether the schedule of plasma administration should be adapted based on residual ADAMTS13 activity deserves further study. Patients with an acquired TTP who suffer a bout during pregnancy should be treated with TPE. Pregnancy does not seem to modify the responsiveness to TPE [73]. However, the consequences of the treatment on the fetus have not been accurately evaluated. Further studies are also needed to specify the use of immunomodulatory drugs in this context.

Childhood thrombotic thrombocytopenic purpura

In children, the ratio of hereditary TTP (USS) to acquired TTP has not been clearly established [19,74–76]. According to the cases in the literature, USS seems more frequent, but this epidemiological data has to be confirmed by a combined analysis of the available national registries.

Management of hereditary thrombotic thrombocytopenic purpura (Upshaw-Schulman syndrome)

In the large majority of cases, USS is a disease of childhood and even neonatal onset [77]. In neonates, exchange transfusion is usually indicated due to severe hyperbilirubinemia. In children, curative treatment of TTP consists of a 10 ml/kg plasma infusion per day that rescues patients from acute episodes with the cessation of hemolysis within 24–48 hours and the normalization of platelets usually within 1 week. However, rescue infusion may not prevent central nervous system and renal involvement. The question of systematic preventive plasma therapy continues to be debated. Approximately one-half of USS patients exhibit a highly recurrent form of the disease that clearly requires prophylaxis, while the other half of USS patients have unpredictable relapses with intervals of several years between TTP bouts and may not be appropriate candidates for prophylaxis. As the diagnosis of TTP can be now made very quickly due to methods that can rapidly measure ADAMTS13 activity, the first question is *when* preventive plasma therapy should be started once the diagnosis of USS is confirmed, especially in children with a neonatal onset. In such a case, is it reasonable to wait for a second TTP bout to occur before deciding on preventive plasma therapy? Should prophylaxis be reevaluated later in childhood to try to reduce the frequency of plasma infusions? These questions are so far unanswered, and the literature demonstrates that prophylactic therapeutic regimens remain heterogeneous in the treatment of pediatric USS [63,77–81]. However, when prophylactic plasma therapy is initiated in the chronic form of USS, 10 ml/kg every 2–4 weeks is usually necessary to maintain remission. In practice, the interval between plasma infusions should be decided according to the platelet count; if the platelet count is below 150 giga/l at the time of infusion, a shorter interval should be scheduled. Prophylactic plasma therapy usually efficiently controls the disease and prevents serious complications. To date, post-plasma therapy alloimmunization against ADAMTS13 has never been demonstrated.

Another question regarding prophylaxis in USS children is whether plasma therapy should be intensified to cover the most frequent triggering factors of TTP bouts in childhood, infections and vaccinations. Also, while there is no consensus in the literature, it seems reasonable to strongly recommend the close monitoring of the platelet count and hemoglobin during such time periods to have the ability to administer plasma as soon as the platelet count drops below 150 giga/l [80].

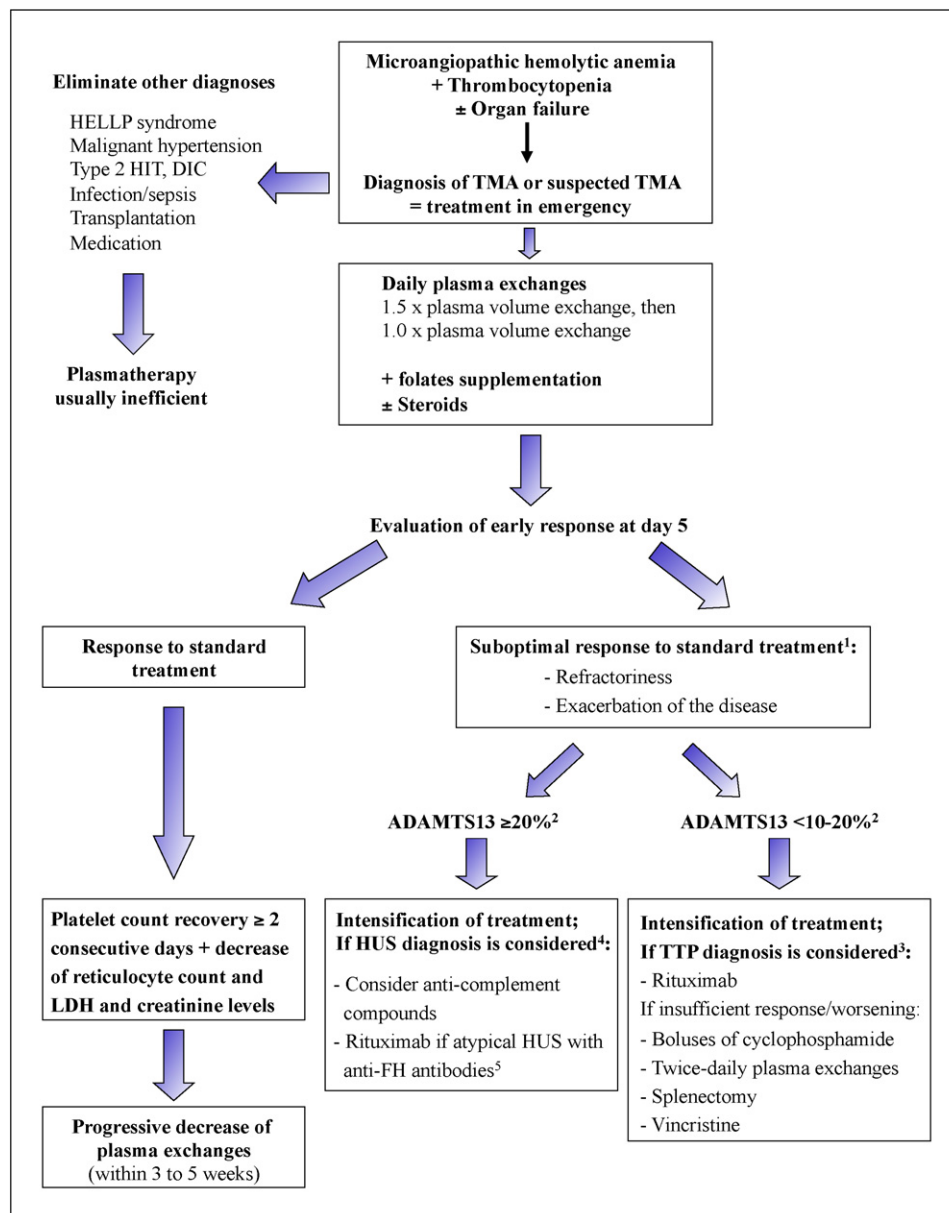


FIGURE 2

Diagnostic and therapeutic strategy in patients with a diagnosis of thrombotic microangiopathy (TMA)

¹TTP is defined as refractory when a patient has not responded to treatment after few days of standard treatment (usually 4 days). Exacerbation is defined as a worsening of the disease while under treatment, during the reduction of the intensity of TPE, or before 30 consecutive days with a normal platelet count. A worsening that occurs more than 30 days after platelet count recovery is usually defined as a relapse.

²If ADAMTS13 activity level is not available at the time of presentation, severe acquired ADAMTS13 deficiency may be predicted based on clinical presentation [10,12].

³Salvage therapy in patients with a suboptimal response to standard treatment (i.e., when no response to treatment is observed after four full days of standard treatment, or when patients experience an exacerbation of the disease under treatment or during the decrease of TPE sessions) is empirical and depends on the clinician's experience. Though there is no consensual hierarchy on what strategy to use, rituximab is increasingly being used as first-line adjuvant therapy. Boluses of cyclophosphamide and splenectomy are a possibility in patients with uncontrolled, life-threatening TTP.

⁴Patients with detectable ADAMTS13 activity probably represent a heterogeneous group of diseases in which the efficacy of salvage procedures such as rituximab, cyclophosphamide, and splenectomy needs to be evaluated.

⁵Atypical hemolytic-uremic syndrome with antibodies directed against the Factor H component of complement is mostly observed in children.

HELLP: Hemolysis, Elevated Liver enzymes, and Low Platelet count; HIT: Heparin-induced thrombocytopenia; DIC: disseminated intravascular coagulopathy.

Management of acquired autoimmune thrombotic thrombocytopenic purpura

Acquired autoimmune TTP very rarely occurs in children and adolescents and only case and short series reports have been published on this subject [82–86]. Like in adults, TPE (usually associated with steroids) is the reference curative treatment [85]. The use of rituximab remains limited to a few cases [85], and the benefit/risk balance of this therapeutic agent in this specific age range needs to be further investigated.

Conclusion and future directions

Both our knowledge of the pathophysiology of TTP and our clinical experience in the treatment of these diseases has clearly improved, and there is no doubt that both will help lead to better management of patients with TTP.

How to further improve the prognosis of thrombotic thrombocytopenic purpura?

The rapid diagnosis and early initiation of an adaptable treatment are clearly related to a favorable prognosis in TTP. The diagnosis of TTP in an emergency setting is challenged by the rarity of the disease, which may lead to a delay in the management that can impact the prognosis. Consequently, there is a crucial need to develop educational programs for generalists, emergency department physicians, and all other specialists possibly involved in the management of TTP that increase their understanding of the recognition and management of the disease. In addition, there should also be educational programs for patients about the typical features suggestive of a relapse. Further, all patients should carry a card that specifies their illness, its characteristics, and the treatment that needs to be started in the case of a relapse. This document should also specify whether the patient has a congenital or an acquired ADAMTS13 deficiency, if they have undergone any previous procedures such as a splenectomy that would make them vulnerable to opportunistic infections, and if they are taking rituximab or other immunomodulatory drugs.

The field of TTP (and TMA in general) is an active area of investigation for new therapies and represents a convincing example of the power of translational medicine. Indeed, as mentioned previously, rituximab is currently being intensively evaluated as an adjuvant therapy in patients with a suboptimal response to standard treatment [40] and even as a neo-adjuvant therapy with TPE (as was recently suggested by the UK group) [39]. However, it is unclear if rituximab should be systematically administered to all patients with TTP because more than 50% of patients recover after being treated with TPE and steroids. Moreover, whether rituximab impacts the incidence of long-term relapses and modifies the natural history of the disease remains to be determined. Other promising potential therapies include plasma-purified ADAMTS13 and recombinant ADAMTS13 protein, the latter being a particularly potentially attractive alternative to plasma as a treatment for TTP when it becomes readily available [87,88]. Recently, compounds aimed at inhibiting the interaction between glycoprotein Ib/IX and VWF have been developed and have shown encouraging results in terms of efficiently inhibiting VWF-mediated platelet aggregation *in vitro* [89]. However, their possible role as adjuvant therapies in TTP and their safety profiles require evaluation in clinical trials. Other therapeutical prospects may include compounds that inhibit VWF polymerization and therapies aimed at protecting the microvascular endothelium and organs from apoptosis and shear-stress-induced injury [90]. [For the diagnostic and therapeutic strategy in patients with a diagnosis of TMA: *figure 2*].

Disclosure of interest: Paul Coppo is member of the Clinical Advisory Boards of Baxter and Alexion.

Acknowledgments: The authors thank Sandrine Malot for technical assistance. This work was funded by grants from the Établissement français du sang (CS/2002/009) and the GIS-Institut des maladies rares (GIS MR0428).

References

- [1] Furlan M, Robles R, Galbusera M, Remuzzi G, Kyrle PA, Brenner B *et al.* von Willebrand factor-cleaving protease in thrombotic thrombocytopenic purpura and the hemolytic-uremic syndrome. *N Engl J Med* 1998; 339(22):1578-84.
- [2] Tsai HM, Lian EC. Antibodies to von Willebrand factor-cleaving protease in acute thrombotic thrombocytopenic purpura. *N Engl J Med* 1998;339(22):1585-94.
- [3] Feys HB, Roodt J, Vandeputte N, Pareyn I, Lamprecht S, van Rensburg WJ *et al.* Thrombotic thrombocytopenic purpura directly linked with ADAMTS13 inhibition in the baboon (*Papio ursinus*). *Blood* 2011; 116(12):2005-10.
- [4] Coppo P, Busson M, Veyradier A, Wynckel A, Poullin P, Azoulay E *et al.* HLA-DRB1*11: a strong risk factor for acquired severe ADAMTS13 deficiency-related idiopathic thrombotic thrombocytopenic purpura in Caucasians. *J Thromb Haemost* 2010;8(4):856-9.
- [5] Levy GG, Nichols WC, Lian EC, Foroud T, McClintick JN, McGee BM *et al.* Mutations in a member of the ADAMTS gene family cause thrombotic thrombocytopenic purpura. *Nature* 2001;413(6855):488-94.
- [6] Motto DG, Chauhan AK, Zhu G, Homeister J, Lamb CB, Desch KC *et al.* Shigatoxin triggers

- thrombotic thrombocytopenic purpura in genetically susceptible ADAMTS13-deficient mice. *J Clin Invest* 2005;115(10):2752-61.
- [7] Moake JL, Rudy CK, Troll JH, Weinstein MJ, Colaninno NM, Azocar J *et al.* Unusually large plasma factor VIII: von Willebrand factor multimers in chronic relapsing thrombotic thrombocytopenic purpura. *N Engl J Med* 1982;307(23):1432-5.
 - [8] Moake JL, Turner NA, Stathopoulos NA, Nolasco LH, Hellums JD. Involvement of large plasma von Willebrand factor (vWF) multimers and unusually large vWF forms derived from endothelial cells in shear stress-induced platelet aggregation. *J Clin Invest* 1986;78(6):1456-61.
 - [9] Ridolfi RL, Bell WR. Thrombotic thrombocytopenic purpura. Report of 25 cases and review of the literature. *Medicine (Baltimore)* 1981;60(6):413-28.
 - [10] Coppo P, Schwarzwinger M, Buffet M, Wynckel A, Clabault K, Presne C *et al.* Predictive features of severe acquired ADAMTS13 deficiency in idiopathic thrombotic microangiopathies: the French TMA reference center experience. *PLoS One* 2010;5(4): e10208.
 - [11] Hovinga JA, Vesely SK, Terrell DR, Lammle B, George JN. Survival and relapse in patients with thrombotic thrombocytopenic purpura. *Blood* 2010;115(8):1500-11 ([quiz 1662]).
 - [12] Bentley MJ, Lehman CM, Blaylock RC, Wilson AR, Rodgers GM. The utility of patient characteristics in predicting severe ADAMTS13 deficiency and response to plasma exchange. *Transfusion* 2010;50(8):1654-64.
 - [13] Raife T, Atkinson B, Montgomery R, Vesely S, Friedman K. Severe deficiency of VWF-cleaving protease (ADAMTS13) activity defines a distinct population of thrombotic microangiopathy patients. *Transfusion* 2004;44(2):146-50.
 - [14] Patschan D, Witzke O, Duhrsen U, Erbel R, Philipp T, Herget-Rosenthal S. Acute myocardial infarction in thrombotic microangiopathies: clinical characteristics, risk factors and outcome. *Nephrol Dial Transplant* 2006;21(6):1549-54.
 - [15] Hawkins BM, Abu-Fadel M, Vesely SK, George JN. Clinical cardiac involvement in thrombotic thrombocytopenic purpura: a systematic review. *Transfusion* 2008;48(2):382-92.
 - [16] Hughes C, McEwan JR, Longair I, Hughes S, Cohen H, Machin S *et al.* Cardiac involvement in acute thrombotic thrombocytopenic purpura: association with troponin T and IgG antibodies to ADAMTS 13. *J Thromb Haemost* 2009;7(4):529-36.
 - [17] Hosler GA, Cusumano AM, Hutchins GM. Thrombotic thrombocytopenic purpura and hemolytic uremic syndrome are distinct pathologic entities. A review of 56 autopsy cases. *Arch Pathol Lab Med* 2003;127(7):834-9.
 - [18] Asherson RA, Cervera R. Microvascular and microangiopathic antiphospholipid-associated syndromes ("MAPS"): semantic or antisemantic? *Autoimmun Rev* 2008;7(3):164-7.
 - [19] Schneppenheim R, Budde U, Oyen F, Angerhaus D, Aumann V, Drewke E *et al.* von Willebrand factor cleaving protease and ADAMTS13 mutations in childhood TTP. *Blood* 2003;101(5):1845-50.
 - [20] Rock GA, Shumak KH, Buskard NA, Blanchette VS, Kelton JG, Nair RC *et al.* Comparison of plasma exchange with plasma infusion in the treatment of thrombotic thrombocytopenic purpura. Canadian Apheresis Study Group. *N Engl J Med* 1991;325(6):393-7.
 - [21] Coppo P, Bussel A, Charrier S, Adrie C, Galicier L, Boulanger E *et al.* High-dose plasma infusion versus plasma exchange as early treatment of thrombotic thrombocytopenic purpura/hemolytic-uremic syndrome. *Medicine (Baltimore)* 2003;82(1):27-38.
 - [22] Pene F, Vigneau C, Auburtin M, Moreau D, Zahar JR, Coste J *et al.* Outcome of severe adult thrombotic microangiopathies in the intensive care unit. *Intensive Care Med* 2005;31(1):71-8.
 - [23] Rock G, Shumak KH, Sutton DM, Buskard NA, Nair RC. Cryosupernatant as replacement fluid for plasma exchange in thrombotic thrombocytopenic purpura. Members of the Canadian Apheresis Group. *Br J Haematol* 1996;94(2):383-6.
 - [24] Zeigler ZR, Gryn JF, Rintels PB. Cryopoor plasma does not improve early response in primary adult thrombotic thrombocytopenic purpura (TTP). *Blood* 1998;92(Suppl. 1): 707a.
 - [25] Bell WR, Braine HG, Ness PM, Kickler TS. Improved survival in thrombotic thrombocytopenic purpura-hemolytic uremic syndrome. Clinical experience in 108 patients. *N Engl J Med* 1991;325(6):398-403.
 - [26] Balduini CL, Gugliotta L, Luppi M, Laurenti L, Klersy C, Pieresca C *et al.* High versus standard dose methylprednisolone in the acute phase of idiopathic thrombotic thrombocytopenic purpura: a randomized study. *Ann Hematol* 2010;89(6):591-6.
 - [27] Rojnuckarin P, Watanaboonyongcharoen P, Akkawat B, Intragumtornchai T. The role of pulse dexamethasone in acquired idiopathic thrombotic thrombocytopenic purpura. *J Thromb Haemost* 2006;4(5):1148-50.
 - [28] Toyoshige M, Zaitzu Y, Okafuji K, Inoue Y, Hiroshige Y, Matsumoto N *et al.* Successful treatment of thrombotic thrombocytopenic purpura with high-dose corticosteroid. *Am J Hematol* 1992;41(1):69.
 - [29] Bobbio-Pallavicini E, Gugliotta L, Centurioni R, Porta C, Vianelli N, Billio A *et al.* Antiplatelet agents in thrombotic thrombocytopenic purpura (TTP). Results of a randomized multicenter trial by the Italian Cooperative Group for TTP. *Haematologica* 1997;82(4):429-35.
 - [30] Rosove MH, Ho WG, Goldfinger D. Ineffectiveness of aspirin and dipyridamole in the treatment of thrombotic thrombocytopenic purpura. *Ann Intern Med* 1982;96(1):27-33.
 - [31] Harkness DR, Byrnes JJ, Lian EC, Williams WD, Hensley GT. Hazard of platelet transfusion in thrombotic thrombocytopenic purpura. *JAMA* 1981;246(17):1931-3.
 - [32] Gordon LI, Kwaan HC, Rossi EC. Deleterious effects of platelet transfusions and recovery thrombocytosis in patients with thrombotic microangiopathy. *Semin Hematol* 1987;24(3):194-201.
 - [33] de la Rubia J, Plume G, Arriaga F, Carpio N, Sanz MA, Marty ML. Platelet transfusion and thrombotic thrombocytopenic purpura. *Transfusion* 2002;42(10):1384-5.
 - [34] Tripathi SP, Deshpande AS, Khadse S, Kulkarni RK. Case of TTP with cerebral infarct secondary to platelet transfusion. *Indian J Pediatr* 2011;78(1):109-11.
 - [35] Coppo P, Lassoued K, Mariette X, Gossot D, Oksenhendler E, Adrie C *et al.* Effectiveness of platelet transfusions after plasma exchange in adult thrombotic thrombocytopenic purpura: a report of two cases. *Am J Hematol* 2001;68(3):198-201.
 - [36] Swisher KK, Terrell DR, Vesely SK, Kremer Hovinga JA, Lammle B, George JN. Clinical outcomes after platelet transfusions in patients with thrombotic thrombocytopenic purpura. *Transfusion* 2009;49(5):873-87.
 - [37] Mannucci PM, Bohm M, Scharrer I, Scheiflinger F. Patterns of changes of anti-ADAMTS13 after plasma exchange. *J Thromb Haemost* 2006;4(6):1405-6.
 - [38] Caramazza D, Quintini G, Abbene I, Coco LL, Malato A, Di Trapani R *et al.* Rituximab for managing relapsing or refractory patients with idiopathic thrombotic thrombocytopenic purpura-haemolytic uraemic syndrome. *Blood Transfus* 2010;8(3):203-10.
 - [39] Scully M, McDonald V, Cavenagh J, Hunt BJ, Longair I, Cohen H *et al.* A phase II study of the safety and efficacy of rituximab with plasma exchange in acute acquired thrombotic thrombocytopenic purpura. *Blood* 2011;118(7):1746-53.
 - [40] Froissart A, Buffet M, Veyradier A. First-line rituximab efficacy and safety in patients with acquired idiopathic thrombotic thrombocytopenic purpura experiencing a sub-optimal response to therapeutic plasma exchange: results of a prospective multicenter phase 2 study. *Crit Care Med* 2012;40(1):104-11.
 - [41] Bobbio-Pallavicini E, Porta C, Centurioni R, Gugliotta L, Vianelli N, Tacconi F *et al.* Vincristine sulfate for the treatment of thrombotic thrombocytopenic purpura refractory to plasma-exchange. The Italian Cooperative Group for TTP. *Eur J Haematol* 1994;52(4):222-6.

- [42] Welborn JL, Emrick P, Acevedo M. Rapid improvement of thrombotic thrombocytopenic purpura with vincristine and plasmapheresis. *Am J Hematol* 1990;35(1):18-21.
- [43] Ziman A, Mitri M, Klapper E, Pepkowitz SH, Goldfinger D. Combination vincristine and plasma exchange as initial therapy in patients with thrombotic thrombocytopenic purpura: one institution's experience and review of the literature. *Transfusion* 2005;45(1):41-9.
- [44] Onundarson PT, Rowe JM, Heal JM, Francis CW. Response to plasma exchange and splenectomy in thrombotic thrombocytopenic purpura. A 10-year experience at a single institution. *Arch Intern Med* 1992;152(4):791-6.
- [45] Kappers-Klunne MC, Wijermans P, Fijnheer R, Croockewit AJ, van der Holt B, de Wolf JT *et al.* Splenectomy for the treatment of thrombotic thrombocytopenic purpura. *Br J Haematol* 2005;130(5):768-76.
- [46] Zieschang M, Kohlhauf M, Hoffler D, Niemeyer R, Prager G. A case of thrombotic thrombocytopenic purpura successfully treated with cyclophosphamide. *Nephron* 1995;69(2):176.
- [47] Centurioni R, Bobbio-Pallavicini E, Porta C, Rodeghiero F, Gugliotta L, Billio A *et al.* Treatment of thrombotic thrombocytopenic purpura with high-dose immunoglobulins. Results in 17 patients. Italian Cooperative Group for TTP. *Haematologica* 1995;80(4):325-31.
- [48] Hand JP, Lawlor ER, Yong CK, Davis JH. Successful use of cyclosporine A in the treatment of refractory thrombotic thrombocytopenic purpura. *Br J Haematol* 1998;100(3):597-9.
- [49] Nosari A, Bernuzzi P, Corneo R, Pungolino E, Muti G, Rossi V *et al.* Late response to cyclosporine in refractory thrombotic thrombocytopenic purpura. *Int J Hematol* 2002;76(3):284-6.
- [50] Itala M, Remes K. Excellent response of refractory life-threatening thrombotic thrombocytopenic purpura to cyclosporine treatment. *Clin Lab Haematol* 2004;26(1):65-7.
- [51] Ahmad HN, Thomas-Dewing RR, Hunt BJ. Mycophenolate mofetil in a case of relapsed, refractory thrombotic thrombocytopenic purpura. *Eur J Haematol* 2007;78(5):449-52.
- [52] Cataland SR, Jin M, Lin S, Kennedy MS, Kraut EH, George JN *et al.* Cyclosporin and plasma exchange in thrombotic thrombocytopenic purpura: long-term follow-up with serial analysis of ADAMTS13 activity. *Br J Haematol* 2007;139(3):486-93.
- [53] Cataland SR, Jin M, Lin S, Kraut EH, George JN, Wu HM. Effect of prophylactic cyclosporine therapy on ADAMTS13 biomarkers in patients with idiopathic thrombotic thrombocytopenic purpura. *Am J Hematol* 2008;83(12):911-5.
- [54] Nguyen L, Li X, Duvall D, Terrell DR, Vesely SK, George JN. Twice-daily plasma exchange for patients with refractory thrombotic thrombocytopenic purpura: the experience of the Oklahoma Registry, 1989 through 2006. *Transfusion* 2008;48(2):349-57.
- [55] Ferrari S, Scheiflinger F, Rieger M, Mudde G, Wolf M, Coppo P *et al.* Prognostic value of anti-ADAMTS 13 antibody features (Ig isotype, titer, and inhibitory effect) in a cohort of 35 adult French patients undergoing a first episode of thrombotic microangiopathy with undetectable ADAMTS 13 activity. *Blood* 2007;109(7):2815-22.
- [56] Peyvandi F, Lavoretano S, Palla R, Feys HB, Vanhoorelbeke K, Battaglioli T *et al.* ADAMTS13 and anti-ADAMTS13 antibodies as markers for recurrence of acquired thrombotic thrombocytopenic purpura during remission. *Haematologica* 2008;93(2):232-9.
- [57] Lotta LA, Mariani M, Consonni D, Mancini I, Palla R, Maino A *et al.* Different clinical severity of first episodes and recurrences of thrombotic thrombocytopenic purpura. *Br J Haematol* 2010;151(5):488-94.
- [58] Veltman GA, Brand A, Leeksa OC, ten Bosch GJ, van Krieken JH, Briet E. The role of splenectomy in the treatment of relapsing thrombotic thrombocytopenic purpura. *Ann Hematol* 1995;70(5):231-6.
- [59] Kremer Hovinga JA, Studt JD, Demarmels Biasiutti F, Solenthaler M, Alberio L, Zwicky C *et al.* Splenectomy in relapsing and plasma-refractory acquired thrombotic thrombocytopenic purpura. *Haematologica* 2004;89(3):320-4.
- [60] Moake JL, Rudy CK, Troll JH, Schafer AI, Weinstein MJ, Colanino NM *et al.* Therapy of chronic relapsing thrombotic thrombocytopenic purpura with prednisone and azathioprine. *Am J Hematol* 1985;20(1):73-9.
- [61] Pasquale D, Vidhya R, DaSilva K, Tsan MF, Lansing L, Chikkappa G. Chronic relapsing thrombotic thrombocytopenic purpura: role of therapy with cyclosporine. *Am J Hematol* 1998;57(1):57-61.
- [62] Allan DS, Kovacs MJ, Clark WF. Frequently relapsing thrombotic thrombocytopenic purpura treated with cytotoxic immunosuppressive therapy. *Haematologica* 2001;86(8):844-50.
- [63] Fujimura Y, Matsumoto M, Kokame K, Isonishi A, Soejima K, Akiyama N *et al.* Pregnancy-induced thrombocytopenia and TTP, and the risk of fetal death, in Upshaw-Schulman syndrome: a series of 15 pregnancies in 9 genotyped patients. *Br J Haematol* 2009;144(5):742-54.
- [64] Tao Z, Anthony K, Peng Y, Choi H, Nolasco L, Rice L *et al.* Novel ADAMTS-13 mutations in an adult with delayed onset thrombotic thrombocytopenic purpura. *J Thromb Haemost* 2006;4(9):1931-5.
- [65] Camilleri RS, Cohen H, Mackie IJ, Scully M, Starke RD, Crawley JT *et al.* Prevalence of the ADAMTS-13 missense mutation R1060W in late onset adult thrombotic thrombocytopenic purpura. *J Thromb Haemost* 2008;6(2):331-8.
- [66] Malak S, Wolf M, Millot GA, Mariotte E, Veyradier A, Meynard JL *et al.* Human immunodeficiency virus-associated thrombotic microangiopathies: clinical characteristics and outcome according to ADAMTS13 activity. *Scand J Immunol* 2008;68(3):337-44.
- [67] Gunther K, Garizio D, Nesara P. ADAMTS13 activity and the presence of acquired inhibitors in human immunodeficiency virus-related thrombotic thrombocytopenic purpura. *Transfusion* 2007;47(9):1710-6.
- [68] Novitzky N, Thomson J, Abrahams L, du Toit C, McDonald A. Thrombotic thrombocytopenic purpura in patients with retroviral infection is highly responsive to plasma infusion therapy. *Br J Haematol* 2005;128(3):373-9.
- [69] Hart D, Sayer R, Miller R, Edwards S, Kelly A, Baglin T *et al.* Human immunodeficiency virus associated thrombotic thrombocytopenic purpura-favourable outcome with plasma exchange and prompt initiation of highly active antiretroviral therapy. *Br J Haematol* 2011;153(4):515-9.
- [70] Francis KK, Kalyanam N, Terrell DR, Vesely SK, George JN. Disseminated malignancy misdiagnosed as thrombotic thrombocytopenic purpura: a report of 10 patients and a systematic review of published cases. *Oncologist* 2007;12(1):11-9.
- [71] Oberic L, Buffet M, Schwarzwinger M, Veyradier A, Clabault K, Malot S *et al.* Cancer awareness in atypical thrombotic microangiopathies. *Oncologist* 2009;14(8):769-79.
- [72] Zakarija A, Kwaan HC, Moake JL, Bandarenko N, Pandey DK, McKoy JM *et al.* Ticlopidine- and clopidogrel-associated thrombotic thrombocytopenic purpura (TTP): review of clinical, laboratory, epidemiological, and pharmacovigilance findings (1989-2008). *Kidney Int Suppl* 2009;112:S20-4.
- [73] Scully M, Starke R, Lee R, Mackie I, Machin S, Cohen H. Successful management of pregnancy in women with a history of thrombotic thrombocytopenic purpura. *Blood Coagul Fibrinolysis* 2006;17(6):459-63.
- [74] Horton TM, Stone JD, Yee D, Dreyer Z, Moake JL, Mahoney DH. Case series of thrombotic thrombocytopenic purpura in children and adolescents. *J Pediatr Hematol Oncol* 2003;25(4):336-9.
- [75] Veyradier A, Obert B, Haddad E, Cloarec S, Nivet H, Foulard M *et al.* Severe deficiency of the specific von Willebrand factor-cleaving protease (ADAMTS 13) activity in a

- subgroup of children with atypical hemolytic uremic syndrome. *J Pediatr* 2003; 142(3):310-7.
- [76] Matsumoto M, Yagi H, Ishizashi H, Wada H, Fujimura Y. The Japanese experience with thrombotic thrombocytopenic purpura-hemolytic uremic syndrome. *Semin Hematol* 2004;41(1):68-74.
- [77] Klukowska A, Niewiadomska E, Budde U, Oyen F, Schneppenheim R. Difficulties in diagnosing congenital thrombotic thrombocytopenic purpura. *J Pediatr Hematol Oncol* 2010;32(2):103-7.
- [78] Bouw MC, Dors N, van Ommen H, Ramakers-van Woerden NL. Thrombotic thrombocytopenic purpura in childhood. *Pediatr Blood Cancer* 2009;53(4):537-42.
- [79] Galbusera M, Noris M, Remuzzi G. Inherited thrombotic thrombocytopenic purpura. *Haematologica* 2009;94(2):166-70.
- [80] Loirat C, Girma JP, Desconclois C, Coppo P, Veyradier A. Thrombotic thrombocytopenic purpura related to severe ADAMTS13 deficiency in children. *Pediatr Nephrol* 2009;24(1):19-29.
- [81] Albaramki JH, Teo J, Alexander SI. Rituximab therapy in two children with autoimmune thrombotic thrombocytopenic purpura. *Pediatr Nephrol* 2009;24(9):1749-52.
- [82] Sato A, Hoshi Y, Onuma M, Sato R, Tsunematsu Y, Isonishi A *et al.* A 9-month-old infant with acquired idiopathic thrombotic thrombocytopenic purpura caused by inhibitory IgG-autoantibody to ADAMTS13. *Pediatr Hematol Oncol* 2010;27(1):53-8.
- [83] Schneppenheim R, Budde U, Hassenpflug W, Obser T. Severe ADAMTS-13 deficiency in childhood. *Semin Hematol* 2004;41(1):83-9.
- [84] Moskowitz NP, Fligman I, Scimeca P, Weinblatt M. Transient TTP in childhood. *Pediatr Blood Cancer* 2009;52(3):424-6.
- [85] McDonald V, Liesner R, Grainger J, Gattens M, Machin SJ, Scully M. Acquired, noncongenital thrombotic thrombocytopenic purpura in children and adolescents: clinical management and the use of ADAMTS 13 assays. *Blood Coagul Fibrinolysis* 2010;21(3):245-50.
- [86] Harambat J, Lamireau D, Delmas Y, Ryman A, Llanas B, Brissaud O. Successful treatment with rituximab for acute refractory thrombotic thrombocytopenic purpura related to acquired ADAMTS13 deficiency: a pediatric report and literature review. *Pediatr Crit Care Med* 2011; 12(2):e90-3.
- [87] Muchitsch EM, Dietrich B, Rottensteiner H, Auer W, Nehrbass D, Gritsch H *et al.* Preclinical testing of human recombinant von Willebrand factor: ADAMTS13 cleavage capacity in animals as criterion for species suitability. *Semin Thromb Hemost* 2010;36(5):522-8.
- [88] Plaimauer B, Kremer Hovinga JA, Juno C, Wolfsegger MJ, Skalicky S, Schmidt M *et al.* Recombinant ADAMTS13 normalizes von Willebrand factor-cleaving activity in plasma of acquired TTP patients by overriding inhibitory antibodies. *J Thromb Haemost* 2011;9(5):936-44.
- [89] Jilma-Stohlawetz P, Gorczyca ME, Jilma B, Siller-Matula J, Gilbert JC, Knobl P. Inhibition of von Willebrand factor by ARC1779 in patients with acute thrombotic thrombocytopenic purpura. *Thromb Haemost* 2011; 105(3):545-52.
- [90] Chen J, Reheman A, Gushiken FC, Nolasco L, Fu X, Moake JL *et al.* N-acetylcysteine reduces the size and activity of von Willebrand factor in human plasma and mice. *J Clin Invest* 2011;121(2):593-603.